



Platelet-rich plasma vs. steroid injections for hamstring injury—is there really a choice?

Peter Yong Soo Park¹ · Chunyan Cai² · Pritish Bawa¹ · Manickam Kumaravel¹

Received: 18 June 2018 / Revised: 26 August 2018 / Accepted: 29 August 2018 / Published online: 17 September 2018
© ISS 2018

Abstract

Objective To assess the effectiveness of pain relief in patients with grade 2 proximal hamstring injury, treated with platelet-rich plasma (PRP) or corticosteroid injection, by using the primary outcome of visual analog scale (VAS) at 1 week and 4 weeks of follow-up.

Materials and methods A single institution retrospective study was performed for image-guided PRP or steroid injections between 12/1/2015 and 10/30/2017 for proximal hamstring injuries. VAS was measured at 1 week and 4 weeks post-injection via telephone interviews and the pain response was recorded into two groups (negative/no change vs. positive). A comparison of pain responses between PRP and steroid was conducted by generalized estimating equation.

Results Among 56 patients, 32 received PRP and 24 received steroid injections with ages from 13 to 75 years old. At 1 week post-injection follow-up, 23 patients (71.9%) from the PRP group and 11 patients (45.8%) from the steroid group showed positive response. After controlling for age, pre-procedure pain level, and gender, the positive response rate in the PRP group was higher than the steroid group (aOR: 4.04, 95% CI: 1.04–15.63, *p* value = 0.04). At 4 weeks post-injection, 23 patients (71.9%) from the PRP group and 13 patients (54.2%) from the steroid group showed positive response with no statistical significance (aOR: 2.48, 95% CI: 0.63–9.79, *p* value = 0.19).

Conclusions The PRP group had shown more favorable response compared to steroid group at 1 week post-injection, which suggests that PRP therapy can be considered as a conservative treatment choice for grade 2 proximal hamstring injuries with better short-term pain relief based on limited pilot data.

Keywords Platelet-rich plasma · Steroid · Hamstring injury

Introduction

Hamstring injuries can be subdivided into proximal, muscle belly, and distal injuries caused by repetitive forceful stretching. Most of the subacute and chronic hamstring injuries can be managed with conservative treatments including image-guided percutaneous therapeutic injection. The role of

platelet-rich plasma (PRP) for musculoskeletal injuries has been more sought after in recent years as there are more positive responses compared to conventional steroid injection. PRP over typical non-operative management (rest, physical therapy, non-steroidal anti-inflammatory drugs) in elbow tendinopathy, rotator cuff tear, and osteoarthritis of the hip have shown positive responses in pain and functional status [1–5]. PRP for professional athletes has become more popular over the years for hamstring injuries where the patient failed the conservative treatments and has enabled an earlier return to the sport with PRP group versus those that received rehabilitation alone [6–10].

PRP is a concentration of platelets and growth factors derived from a small amount of blood. Once a sample of blood is collected, it undergoes centrifugation, which separates the concentrates of platelets and growth factors. There are various growth factors such as platelet-derived growth factor, vascular endothelial growth factor, transforming growth factor- β 1,

✉ Peter Yong Soo Park
peter.y.park@uth.tmc.edu

¹ Department of Diagnostic & Interventional Imaging, McGovern Medical School, The University of Texas Health Science Center at Houston, 6431 Fannin St. MSB 2.130B, Houston, TX 77030, USA

² Department of Internal Medicine, McGovern Medical School, The University of Texas Health Science Center at Houston, 6410 Fannin St. UTPB 1100.08, Houston, TX 77030, USA

fibroblast growth factor, and epidermal growth factor that promote collagen formation, stimulate angiogenesis, and modulate matrix formation [11–14]. Steroid injections are known to be effective short-term anti-inflammatory drugs, but the potential adverse effects of steroid injections such as tendon rupture, skin atrophy, flushing, weight gain, depigmentation, or cellulitis can be potential issues [15–17]. On the other hand, PRP is relatively safe to use as one's own platelets are injected with minimal complications of hematoma, venous thrombosis, and infection at the phlebotomy site [18, 19].

The aim of this study is to assess the effectiveness of PRP vs. steroid injection for grade 2 proximal hamstring injuries by using the primary outcome of the visual analog scale (VAS), a pain scale at post-injection 1 week and 4 weeks of follow-up. The role and effect of PRP therapy in hamstring injury are not completely understood. The potential benefits to patients will be an increased understanding of the effectiveness of PRP hamstring injections for pain relief compared to popular and conventional steroid injection.

Methods

After institutional review board approval with informed consent from all patients, the records of patients diagnosed as grade 2 proximal hamstring injury in the general population were reviewed retrospectively at the author's institution between January 1, 2015 and December 31, 2017, who received PRP or steroid injections with sample size of 56 (age range, 13–75 years old). These patients were sent and referred to our imaging center by the ordering physicians for either PRP or steroid injection. Inclusion criteria include patients who were symptomatic with grade 2 partial tear of the proximal hamstring injury, pre-screened and diagnosed with MRI, and receiving PRP for the first time. Grade 2 proximal hamstring tendonitis was defined as less than 50% cross-sectional tear of hamstring origin of ischial tuberosity [1]. No full-thickness tears or bony avulsions were included in this study. Patients who are active or retired professional athletes or any patients who received PRP or hamstring surgery in the past were excluded. The primary outcome of VAS at 1 week and 4 weeks post-injection was obtained with follow-up telephone interviews by two certified nurses for each patient treated with PRP and steroids. The comparison of the pain scale prior to the procedure performed to the ones measured at post-injection 1 week and 4 weeks were recorded. The pain scale is from 0 to 10, where 10 is the worst pain and 0 is no pain. VAS was recorded into two separate pain response groups: “negative/no change” vs. “positive”. A difference of more than or equal to 2 points between the pre and post-procedure pain level were used to record a positive response to be clinically significant [18].

Patients received a single PRP injection prepared using the Arthrex® Autologous Conditioned Plasma Double Syringe System (Naples, FL, USA). Two certified nurses drew the patient's blood volume of 10 ml followed by a single-step centrifugation for 5 min at 1500 rpm. The PRP was harvested post centrifugation. Harvest volume is about 2–5 ml, which contains about 300,000–500,000 platelets concentration/ μ l. Prepared PRP was consistently given for each patient less than 30 min from the time the sample blood was collected to avoid any potential unnecessary platelet activation before use. PRP was injected under ultrasound or fluoroscopic guidance based on the operator's and patient's preference and performed through the substance of the hamstring muscle attachment site at the site of maximum symptom, by post-musculoskeletal trained faculty with different years of experience ranging from 2 to 15 years (Figs. 1 and 2). The patient was positioned prone and proximal hamstring injection site was sterilized. Only superficial skin local anesthetic lidocaine was used, not given deeper into the attachment site of proximal hamstring. A 22-gauge needle was used and positioned under either fluoroscopic or ultrasound guidance and injected from medial to lateral facet of the ischial tuberosity, an attachment site of origin of hamstring muscle. Potential adverse effects include post-injection pain up to 48 h for both steroid and PRP injections, which are commonly expected and asked during telephone interviews. Presentation of any major complications such as large hematoma or signs of infection were asked during the telephone interviews.

During the 3-year study period, there were 56 patients eligible for this retrospective study (32 patients received PRP and 24 received steroid). With this sample size, assuming the positive response rate in the steroid group is around 40%, we have 80% power to detect an absolute difference of 26% in positive response rate at a significance level of 0.05. Descriptive statistics (mean \pm standard deviation for continuous variables and frequency and percentage for categorical variables) was reported for demographics, pre-procedure pain, and post-injection responses. The comparison of pain response rate between patients treated with PRP and steroid was conducted by Chi-square test. Multivariable analysis was conducted to compare pain response rate between PRP and steroid after controlling for potential confounding effects (age, gender, and pre-procedure pain level). Since the responses were repeatedly collected at both 1 and 4 weeks post-injection follow-up, within the same patient, these two responses could be correlated with each other. To account for these correlations, we applied the generalized estimation equation to analyze this repeated measurements data through the specification of a working correlation structure [18]. Adjusted odds ratio (aOR) of having positive response between PRP vs. steroid along with 95% confidence interval (CI) were reported. All analyses were performed using SAS 9.4 (Cary, NC, USA) and a *p* value less than 0.5 was considered as significant.

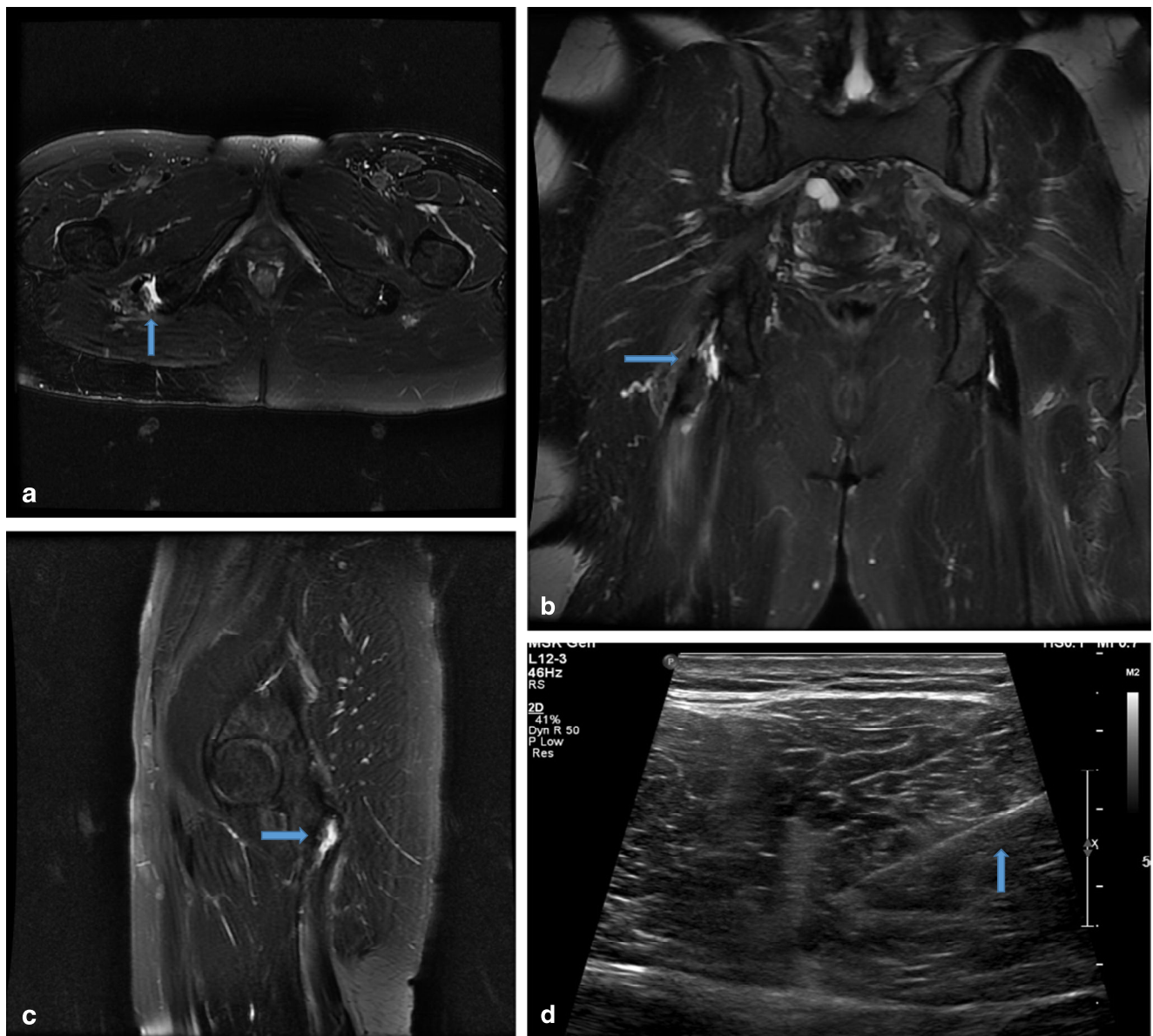


Fig. 1 **a** Axial short tau inversion recovery (STIR) sequence MRI of the thighs in a 28-year-old male with grade 2 injury of the right semimembranosus tendon at the proximal attachment site demonstrating muscle edema and fluid (*blue arrow*). **b** Coronal STIR sequence MRI of the thighs in the same patient with grade 2 injury of right semimembranosus tendon at the proximal attachment site demonstrating

muscle edema and fluid (*blue arrow*). **c** Sagittal STIR sequence MRI of the right thigh in same patient with grade 2 injury of the right semimembranosus tendon at the proximal attachment site demonstrating muscle edema and fluid (*blue arrow*). **d** Longitudinal grayscale ultrasound image. Injection of 5 cc of PRP at the site of hamstring injury with needle (*blue arrow*)

Results

The total sample size was 56 patients. Out of total 56 patients, 32 received PRP and 24 received steroid with ages ranging from 13 to 75 years old and mean \pm standard deviation of age at 34.4 ± 16.9 and 49.7 ± 14.0 , respectively (Table 1). Out of 32 patients who received PRP, 20 received it under ultrasound and 12 under fluoroscopy. Out of 24 patients who received steroids, ultrasound and fluoroscopy had 12 patients each, respectively. At 1-week post-injection follow-up, 23 patients

(71.9%) from the PRP group showed a positive response, which is statistically different from that of the steroid group, with 11 patients (45.8%) showing a positive response (p value = 0.05) in the univariable analysis (Table 1, Figs. 3 and 4). After controlling for age, pre-procedure pain level (≤ 5 vs >5) and gender, the odds of having a positive response rate in the PRP group is around four times compared to steroid group (aOR: 4.04, 95% CI: 1.04–15.63, p value = 0.04). At 4-week post-injection follow-up, 23 patients (71.9%) from the PRP group and 13 patients (54.2%) from the steroid group showed

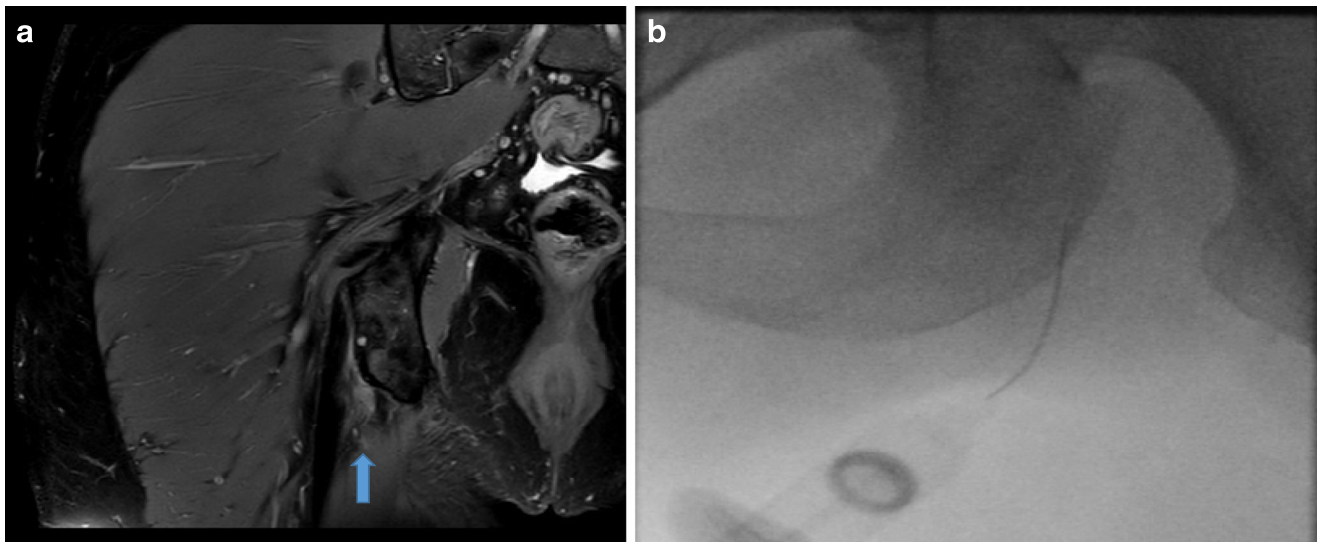


Fig. 2 **a** Coronal proton density (PD) sequence MRI of a 42-year-old female with low-grade partial thickness tear of the right hamstring origin at ischial tuberosity (blue arrow). **b** Fluoroscopic-guided PRP injection at the right hamstring origin

a positive response, which did not reach the statistical significance p value of 0.17 in the univariable analysis (Table 1, Figs. 3 and 4). After controlling for age, pre-procedure pain level, and gender, no statistically significant positive pain response rate between PRP vs. steroid groups (aOR: 2.48, 95% CI: 0.63–9.79, p value = 0.19) were observed. In our patient population, no significant adverse effects such as local hematoma, vascular thrombosis, or infection from both PRP and steroid groups were recorded during 1-week and 4-week follow-up.

Discussion

Historically, conventional corticosteroid injections were utilized by many clinicians to treat the pain and inflammation of musculoskeletal injuries due to cost-effectiveness and known short-term pain relief. However, the concern for

potential complications from steroid injection such as tendon rupture, skin depigmentation, flushing, or weight gain was unavoidable [19, 20]. Therefore, many clinicians were seeking a novel non-operative approach such as PRP therapy in treating various ligamentous tendinous injuries despite the fact that PRP therapy is not always covered by insurance. The safety of PRP is well established with minimal complications such as local hematoma, infection, or thrombosis at the phlebotomy site, but the PRP efficacy has not yet been confirmed for proximal hamstring injury [21]. This study demonstrates that in grade 2 proximal hamstring injuries, PRP can be considered as an alternative therapy compared to popular and conventional steroid injection. Many of the patients were referred to our institution by primary care physicians or orthopedic surgeons prior to any invasive surgical options being considered for subacute to chronic hamstring injuries. In our single academic center experience, after controlling age, gender, and pre-procedure pain level, at 1-week post-injection, the PRP group

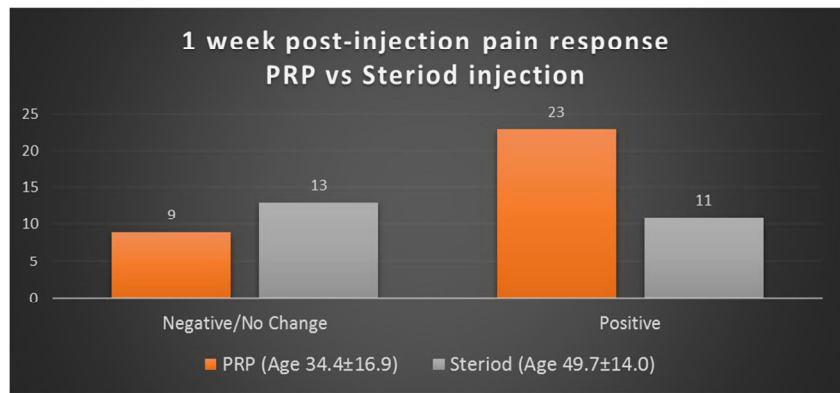
Table 1 Comparison of patient characteristics and outcomes between patients treated with PRP and steroid injections through univariable analysis

Variable	Total ($N = 56$)	PRP ($N = 32$)	Steroids ($N = 24$)	p value
Age, mean \pm SD	41.0 \pm 17.4	34.4 \pm 16.9	49.7 \pm 14.0	< 0.001 [†]
Male, n (%)	29 (51.8)	17 (53.1)	12 (50.0)	0.82 ^c
Pre-procedural pain ≤ 5 , n (%)	23 (41.1)	12 (37.5)	11 (45.8)	0.53 ^c
Response at 1 week, n (%)	$N = 56$	$N = 32$	$N = 24$	0.05 ^c
Negative/No change	22 (39.3)	9 (28.1)	13 (54.2)	
Positive	34 (60.7)	23 (71.9)	11 (45.8)	
Response at 4 weeks, n (%)	$N = 56$	$N = 32$	$N = 24$	0.17 ^c
Negative/No change	20 (35.7)	9 (28.1)	11 (45.8)	
Positive	36 (64.3)	23 (71.9)	13 (54.2)	

^c p values obtained by Chi-square test

[†] p values obtained by two-sample t test

Fig. 3 One-week post-injection pain response between PRP vs. steroid injection



has shown more positive response compared to the steroid group, which suggests that PRP can provide better short-term pain relief. At 4 weeks post-injection, pain response was not statistically significant.

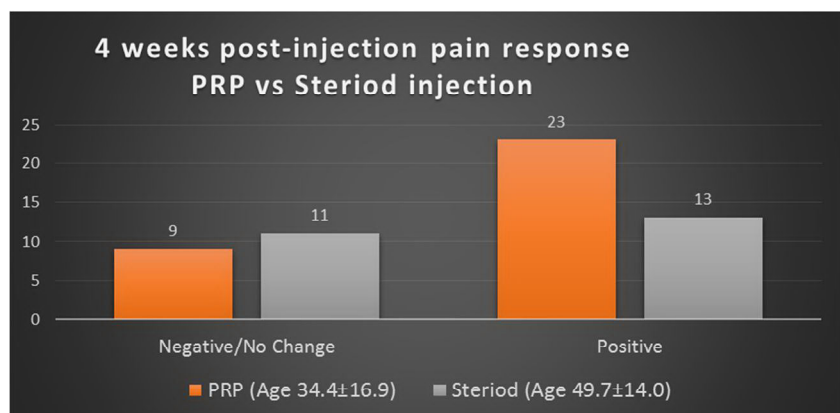
There are several limitations in this study to acknowledge. The inherent biases and limitations of retrospective single-center study limited the study with selection bias and recall biases on follow-up telephone interviews at post-injection 1 week and 4 weeks. For instance, a selection bias from clinicians choosing PRP over steroids due to minimal post-treatment complications should be considered. Furthermore, a limited sample size reduced the power of the study to evaluate the long-term pain relief. Retrospectively, measuring other assessments, such as long-term follow-up at 6 months and functional scores, could have helped to further evaluate the potential long-term efficacy of PRP therapy on the hamstring injury. From our gathered interview, patients who demonstrated a positive response after PRP injection reported that their functional status improved with short-term pain relief within 1–4 weeks.

There are other factors that could have potentially contributed to the pain responses of patients. There is a possibility that procedures performed by personnel with different levels of experience could have impacted the effectiveness of injection. Although this was not assessed in our study, other potential factors to consider are different imaging modality

(ultrasound or fluoroscopic-guided), how the patient received therapy, and how this may have impacted the pain responses. Age may play a potential factor as well as the younger population may respond to therapy differently than the older population. The PRP group had a younger group of patients with average age of 34.4–years-old and 49.7–years-old for the steroid group, which suggested that younger patients likely desired to try out a novel treatment method. Furthermore, there is no current standardization in PRP preparation technique, but a single spinning technique during separation process has been preferred [12]. Thus, the difference in technique in preparation of PRP can potentially affect the effectiveness of PRP therapy.

There is a lack of studies on the comparison between PRP versus steroid injections for the proximal hamstring injuries in the current literature. More active research studies on PRP on many types of musculoskeletal injuries are produced with increasing number of uses of PRP in the clinical setting. In a recent double-blind randomized controlled trial, PRP showed improvements in activities of daily living and sport-specific function at 6 months compared to whole-blood injections [22, 23]. Another randomized trial study demonstrated that use of PRP for grade 2 hamstring injury along with rehabilitation vs. rehabilitation alone was more effective in lowering pain scores [24]. For other sports injuries, such as tennis elbow, PRP showed better 6-month follow-up pain scores

Fig. 4 Four-week post-injection pain response between PRP vs. steroid injection



whereas corticosteroid groups provided a short-term pain relief with reports of tendon degeneration at 6 months [25, 26].

In conclusion, our data suggested that PRP therapy can provide better short-term pain relief within a week compared to the steroid in grade 2 proximal hamstring injury. Assessing long-term benefits of PRP therapy compared to steroid with more systemic functional assessment scores and randomized control study can further support and evaluate the clinical efficacy. By considering the minimal side effects of PRP reported in the current literature compared to conventional steroid injections, our single-center experience adds more perspectives on PRP therapy as a potential logical non-operative treatment option.

Compliance with ethical standards

Conflict of interest The authors declare that they have no conflicts of interest.

References

- Lempainen L, Sarimo J, Mattila K, et al. Proximal hamstring tendinopathy: results of surgical management and histopathologic findings. *Am J Sports Med.* 2009;37:727–34.
- Chaudhury S, De La Lama M, Adler RS, et al. Platelet-rich plasma for the treatment of lateral epicondylitis: sonographic assessment of tendon morphology and vascularity (pilot study). *Skelet Radiol.* 2013;42:91–7.
- Van Den Dolder J, Mooren R, Vloon A, et al. Platelet-rich plasma: quantification of growth factor levels and the effect on growth and differentiation of rat bone marrow cells. *Tissue Eng Part A.* 2010;16:1021–9.
- Sampson S, Gerhardt M, Mandelbaum B. Platelet-rich plasma injection grafts for musculoskeletal injuries: a review. *Curr Rev Musculoskeletal Med.* 2008;1:165–74.
- Menetrey J, Kasemkijwattana C, Day C, et al. Growth factors improve muscle healing in vivo. *J Bone Joint Surg (Br).* 2000;82:131–7.
- Crane D, Everts P. Platelet-rich plasma (PRP) matrix grafts. *Pract Pain Manag.* 2008;8(1):12–26.
- Foster T, Puskas B, Mandelbaum B, et al. Platelet-rich plasma from basic science to clinical applications. *AM J Sports Med.* 2009;37:2259–72.
- Karli D, Robinson B. Platelet-rich plasma for hamstring tears. *Pract Pain Manag.* 2010;10(5):17–18.
- Habib GS, Saliba W, Nashashibi M. Local effects of intra-articular corticosteroids. *Clin Rheumatol.* 2010;29:347–56.
- Diiorio TM, Burkholder JD, Good RP, Parvizi J, Sharkey PF. Platelet-rich plasma does not reduce blood loss or pain or improve range of motion after TKA. *Clin Orthop Relat Res.* 2012;470:138–43.
- Lai LP, Stitik TP, Foye PM, Georgy JS, Patibanda V, Chen B. Use of platelet-rich plasma in intra-articular knee injections for osteoarthritis: a systematic review. *PM R.* 2015;7:637–48.
- Milants C, Bruyere O, Kaux JF. Responders to platelet-rich plasma in osteoarthritis: a technical analysis. *Biomed Res Int.* 2017;2017:7538604.
- Hamid MS, Mohamed Ali MR, Yusof A, et al. Platelet-rich plasma injections for the treatment of hamstring injuries: a randomized controlled trial. *Am J Sports Med.* 2014;42(10):2410–8.
- Mlynarek RA, Kuhn AW, Bedi A. Platelet-rich plasma in orthopedic sports medicine. *Am J Orthop.* 2016;45(5):290–326.
- Wetzel RJ, Patel RM, Terry MA. Platelet-rich plasma as an effective treatment for proximal hamstring injuries. *Orthopedics.* 2013;36(1):e64–70.
- De Vos RJ, Weir A, van Schie HT, et al. Platelet-rich plasma injection for chronic Achilles tendinopathy: a randomized controlled trial. *JAMA.* 2010;303(3):144–9.
- De Vos RJ, Windt J, Weir A. Strong evidence against platelet-rich plasma injections for chronic lateral epicondylar tendinopathy: a systematic review. *Br J Sports Med.* 2014;48:952–6.
- Bird SB, Dickson EW. Clinically significant changes in pain along the visual analog scale. *Ann Emerg Med.* 2001;38:639–43.
- Nourissat G, Ormetti P, Berenbaum F, et al. Does platelet-rich plasma deserve a role in the treatment of tendinopathy? *Joint Bone Spine.* 2015;82(4):230–4.
- Dean BJ, Lostis E, Oakley T, et al. The risks and benefits of glucocorticoid treatment for tendinopathy: a systemic review of the effects of local glucocorticoid on tendon. *Semin Arthritis Rheum.* 2014;43(4):570–6.
- Drezner JA. Practical management: hamstring muscle injuries. *Clin J Sport Med.* 2003;13(1):48–52.
- Bava ED, Barber FA. Platelet-rich plasma products in sports medicine. *Phys Sportsmed.* 2011;39(3):94–9.
- Davenport KL, Campos JS, Nguyen J, et al. Ultrasound-guided intratendinous injections with platelet-rich plasma or autologous whole blood for treatment of proximal hamstring tendinopathy. *J Ultrasound Med.* 2015;34:1455–63.
- Hamid MS, Ali MR, Yusof A, et al. Platelet-rich plasma: an adjuvant to hasten hamstring muscle recovery. A randomized controlled trial protocol. *BMC Musculoskelet Disord.* 2012;13:138.
- Gautam VK, Verma S, Batra S, et al. Platelet-rich plasma versus corticosteroid injection for recalcitrant lateral epicondylitis: clinical and ultrasonographic evaluation. *J Orthop Surg.* 2015;23(1):1–5.
- Liang KY, Zeger SL. Longitudinal data analysis using generalized linear models. *Biometrika.* 1986;73(1):13–22.